

Clinical Case Report of Hydrogen Peroxide Poisoning is Treated by Hyperbaric Oxygen Therapy

© Nguyen Dang Duc¹, © Nguyen Phuong Sinh², © Lam Nguyen Hong Anh²

¹ Poison Control Center, Bach Mai Hospital, Hanoi, Vietnam

² Thai Nguyen University of Medicine and Pharmacy, Thai Nguyen City, Vietnam

Abstract

Hydrogen peroxide is a commonly used oxidizing agent with many different uses such as: as a multi-purpose disinfectant, non-chlorine bleach, hair dye, chlorine neutralizer in water, as a cleaning agent, bleaching in paper production, making wound cleaning agents, sterilizing ophthalmic instruments, etc. Owing to its applications in many fields, ingestion of hydrogen peroxide is not a rare case of poisoning. A 30-year-old female patient presented to our poison control center because of epigastric pain after drinking industrial hydrogen peroxide. Physical examination revealed that the patient was conscious, had no signs of infection, was hemodynamically stable, and had abdominal tenderness in many epigastric areas. Computed tomography results showed air in the biliary tract in the liver, air in the stomach wall, and poor drug enhancement in the stomach wall. Faced with the risk of gastric wall necrosis and gas embolism, the patient was prescribed hyperbaric oxygen therapy (HBO). After 3 days of hyperbaric oxygen treatment, the patient's clinical condition improved significantly. This article aims to discuss the mechanism of injury in hydrogen peroxide poisoning and hyperbaric oxygen therapy HBO in concentrated hydrogen peroxide poisoning.

Keywords: Hydrogen peroxide poisoning, hyperbaric oxygen, therapy

Introduction

Hydrogen peroxide, or hydrogen peroxide (often called hydrogen peroxide, with the chemical formula H_2O_2), is a liquid oxidant with viscous and strong oxidizing properties (1). This compound can be absorbed into the body through the digestive tract, respiratory tract, and skin. Of these, absorption through the gastrointestinal tract accounts for most recorded poisoning cases. There are three main mechanisms that cause hydrogen peroxide poisoning: corrosive damage, oxygen gas formation and lipid peroxidation (2). Depending on the concentration of the oral solution, it will cause different clinical conditions. In this report, we present the case of a patient with hydrogen peroxide poisoning at the 18th hour with signs of severe stomach damage and many air bubbles in the stomach wall.

Case Report

A 30-year-old female patient was admitted to the hospital because she consumed hydrogen peroxide.

History: No previous chronic or mental illness detected.

Development: According to family members, during the days near the hospital, the patient was scammed for money online but did not tell anyone. At approximately 5:00 a.m. on January 11, 2024, the patient drank about 100 mL of industrial hydrogen peroxide with a concentration of 50% and vomited an unknown amount after drinking. The patient then used a knife to cut herself on her right wrist and elbow. At 6 a.m. on January 11, 2024, family members discovered the patient unconscious in the bathroom, with wounds on her wrist and elbow bleeding profusely. The patient was taken to Ninh Binh Provincial General Hospital for stitches to stop the bleeding.



Corresponding Author: Lam Nguyen Hong Anh MD, Thai Nguyen University of Medicine and Pharmacy, Thai Nguyen City, Vietnam

Phone: +0973221357 **E-mail:** lamnguyenhonganh@gmail.com **ORCID ID:** orcid.org/0009-0002-7362-6971

Cite this article as: Duc ND, Sinh NP, Anh LNH. Clinical Case Report of Hydrogen Peroxide Poisoning is Treated by Hyperbaric Oxygen Therapy. Eurasian J Emerg Med. 2024;23(2): 149-51.

Received: 21.02.2024

Accepted: 18.03.2024



©Copyright 2024 The Emergency Physicians Association of Turkey / Eurasian Journal of Emergency Medicine published by Galenos Publishing House. Licenced by Creative Commons Attribution-NonCommercial-NoDerivatives (CC BY-NC-ND) 4.0 International License.

Computed tomography (CT) scan of the abdomen shows: air in the biliary tract in the liver, air in the stomach wall, and poor drug enhancement of the stomach wall.

Diagnosis: Hydrogen peroxide poisoning followed by complications of organ perforation; the right wrist wound was stitched to stop the bleeding. Transferred to the Poison Control Center at 0:00 on January 12, 2024, in the following condition: awake, pink skin and mucous membranes, pulse 65 beats/min, blood pressure 110/70 mmHg, no difficulty breathing, no sore throat, soft abdomen, no bloating, no upper abdominal pain, taste and bowel movements were normal, and the right forearm was bandaged. Blood formula, blood chemistry, and blood coagulation tests showed no abnormalities, blood gasses showed no acid-base disorders.

Abdominal MSCT (January 12 in 2024, 10 a.m.): Image of wall thickening and poor enhancement in the pyloric antral area with air in the stomach wall; no abnormalities of the visceral vascular system were observed (Figure 1).

Thoracic MSCT (January 12 in 2024, 10 a.m.): consolidation and partial collapse of the upper and lower lobes of the lungs on both sides. Little pleural fluid on both sides.

The patient was treated: Fluid infusion, fasting, intravenous nutrition, intravenous esomeprazole 40 mg 2 times/day, and hyperbaric oxygen breathing on the same day.

At 8:00 p.m. on January 12, 2024, after the first hyperbaric oxygen therapy (HBO) breath, the patient underwent CT scan and showed normal drug enhancement in the stomach wall as well as a large decrease in the amount of air in the wall (Figure 2); therefore, the patient continued the prescription. Breathe HBO on January 13 and 14 in 2024.

After 3 days of breathing HBO, the clinical condition improved, the patient had less abdominal pain, no difficulty breathing, and no signs of embolism.

Discussion

Hydrogen peroxide is a clear, colorless, odorless liquid that usually exists in solutions with concentrations ranging from 3 to 90% (3). This is a relatively unstable substance. It is easily decomposed into water and oxygen gas and generates heat in the presence of alkalis, metals, and catalase. Normally, it reacts as an oxidizer, but many reactions in which it reacts as a reducing agent release oxygen as a byproduct. In addition, it also generates inorganic and organic peroxides very quickly.

There are three main poisoning mechanisms of hydrogen peroxide: corrosive damage, oxygen gas formation, and lipid peroxidation.

Swallowing 3% hydrogen peroxide usually causes only mild gastritis. However, direct contact or ingestion of concentrated solution (over 35%) can cause skin corrosion and mucosal blistering, ulceration, or gastrointestinal perforation. Corrosion can also occur in the respiratory tract if inhaled and can lead to airway spasm requiring intubation and mechanical ventilation (4).

Ingestion of concentrated hydrogen peroxide can produce significant amounts of oxygen gas. with 30 mL of 35% solution, 3.5 L of oxygen gas can be produced. Hydrogen peroxide can be absorbed directly in the stomach wall and then released into the blood. When this amount of oxygen exceeds the maximum solubility of the blood, the risk of gas-induced hypervascularity increases, especially in the portal venous system, gastric wall, and cerebral and pulmonary vessels. Intravascular foaming can decrease the right ventricular output.

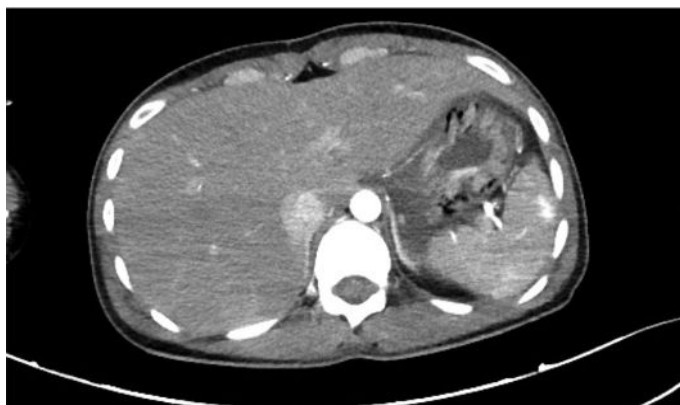

Figure 1. CT scan showing air in the stomach wall
CT: Computed tomography

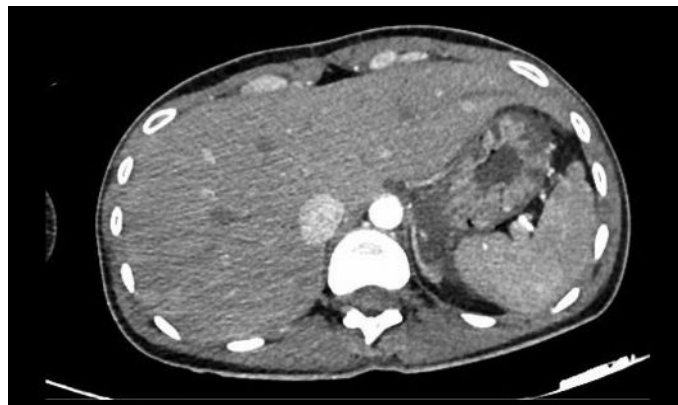


Figure 2. CT scan after the first HBO breath
CT: Computed tomography, HBO: Hyperbaric oxygen therapy

Hydrogen peroxide can be directly toxic to cells through oxidation lipids.

In our clinical case, many air bubbles appeared in the stomach wall.

As well as reduced enhancement of the gastric wall, indicating that the risk of gastric wall necrosis is very high. Faced with this situation, the early removal of air bubbles is the top priority. Hyperbaric oxygen therapy has been applied to help increase the solubility of oxygen in the blood. Therefore, it helps us quickly solve the problem of air bubbles and gastric perfusion. In the patient above, immediately after the first breath, the amount of air decreased significantly. The clinical condition improved rapidly after 3 days of treatment.

Conclusion

Hydrogen peroxide poisoning causes different clinical conditions, depending on many factors such as route of exposure, concentration, and amount of contact. In some cases, the formation of many air bubbles increases the risk of embolism or tissue necrosis due to compression. HBO is considered a treatment to help improve the above condition and provide us with more opportunities to save patients' lives.

Ethics

Informed Consent: Consent form was filled out by all participants.

Authorship Contributions

Surgical and Medical Practices- Concept - Design - Data Collection or Processing - Analysis or Interpretation - Literature Search - Writing: N.D.D., N.P.S., L.N.H.A.

Conflict of Interest: No conflict of interest was declared by the authors.

Financial Disclosure: The authors declared that this study received no financial support.

References

1. Pritchett S, Green D, Rossos P. Accidental ingestion of 35% hydrogen peroxide. *Can J Gastroenterol.* 2007;21:665-7.
2. Watt BE, Proudfoot AT, Vale JA. Hydrogen peroxide poisoning. *Toxicol Rev.* 2004;23:51-7.
3. .Ghai S, O'Malley ME. Portal vein gas resulting from ingestion of hydrogen peroxide. *AJR Am J Roentgenol.* 2003;181:1719-20.
4. Mullins ME, Beltran JT. Acute cerebral gas embolism from hydrogen peroxide ingestion successfully treated with hyperbaric oxygen. *J Toxicol Clin Toxicol.* 1998;36:253-6.