


CASE REPORT

Open Access



Asystole during suspension laryngoscopy associated with vagal reflex or carotid sinus hypersensitivity: a case report

Quan Quang Luu^{1*} , Thai Quoc Phan¹, Yen Thi Thu Phan¹ and Khuong Kinh Luu¹

Abstract

Background Asystole during suspension laryngoscopy is a rare but potentially life-threatening complication if not promptly identified and treated.

Case presentation A 62-year-old Vietnamese man developed sudden asystole during the insertion of a suspension laryngoscope for microlaryngeal surgery. The event was immediately recognized and rapidly reversed through prompt removal of the instrument, initiation of external chest compressions, and administration of intravenous atropine. Vagal reflex triggered by laryngeal stimulation was identified as the likely cause. However, carotid sinus hypersensitivity may have either contributed in conjunction with the vagal reflex or constituted an independent etiology.

Conclusion This case highlights that gentle surgical manipulation and avoidance of excessive cervical extension may help prevent severe bradycardia or asystole during suspension laryngoscopy. Vigilant monitoring and readiness for resuscitation remain essential for patient safety during suspension laryngoscopy.

Keywords Case report, Suspension laryngoscopy, Vagal reflex, Carotid sinus hypersensitivity, Asystole

Background

Suspension laryngoscopy is a widely employed technique to access the laryngeal structures during microlaryngeal surgery [1]. Although generally safe, this procedure typically induces a sympathetic response, resulting in tachycardia and hypertension [1, 2]. However, excessive parasympathetic stimulation may lead to bradycardia or even asystole [1–6]. Vagal reflex (VR) has been identified as the principal cause, typically triggered by direct stimulation of the laryngeal region [2, 4]. Moreover, carotid sinus hypersensitivity (CSH), induced by neck

hyperextension and mechanical pressure on the cervical region, may also provoke asystole [6, 7].

We present a case of sudden asystole during suspension laryngoscopy that was promptly recognized and managed, thereby highlighting the importance of monitoring, prevention, and resuscitative preparedness in anesthetic practice.

Case presentation

A 62-year-old Vietnamese man [157 cm, 60 kg, body mass index (BMI) 24.3 kg/m²] was admitted with persistent hoarseness unresponsive to medical therapy. His medical history included well-controlled hypertension managed with losartan 25 mg daily, with no history of syncope. He had a 20-pack-year smoking history and occasional alcohol consumption. He reported no known drug or food allergies and no previous surgical interventions. There was no family history of arrhythmia or

*Correspondence:

Quan Quang Luu
quanlq@tahospital.vn

¹ Department of Anesthesiology, Tam Anh General Hospital, Ho Chi Minh City, Vietnam



syncope. Otolaryngology endoscopy revealed a right vocal cord polyp, for which microlaryngeal excision was indicated. Preoperative anesthetic assessment showed normal findings on electrocardiogram (ECG), chest radiograph, laboratory tests, and transthoracic echocardiography. The airway evaluation was classified as Mallampati class II, with no limitations in neck mobility.

On the morning of surgery, losartan was replaced with amlodipine (5 mg). In the operating room, standard monitoring devices, including an ECG, noninvasive blood pressure (BP), pulse oximetry, and temperature, were attached. Vital signs before induction were as follows: sinus rhythm at 65 beats per minute, BP at 150/80 mmHg, respiratory rate at 16 breaths per minute, SpO₂ at 98%, and temperature at 36.8 °C. Preoxygenation was performed with 6 L/min of O₂ via a face mask at 100% FiO₂ until the end-tidal O₂ was greater than 80%. Anesthesia induction was performed with sufentanil (15 mcg), propofol (150 mg), and rocuronium (50 mg). Endotracheal intubation with a 6.5 mm cuff-reinforced endotracheal tube using a Macintosh curved blade was successful on the first attempt, with no hemodynamic fluctuations. Anesthesia was maintained with 2% sevoflurane and 50% FiO₂. During surgical field preparation, an additional 10 mcg of sufentanil was administered, and minimum alveolar concentration (MAC) reached 0.9 approximately 2 min prior to the insertion of the suspension laryngoscope. At that time, sinus rhythm was 58 beats per minute and BP was 100/60 mmHg. During the insertion of the suspension laryngoscope, the monitor alarm was triggered for bradycardia (sinus rhythm 40 bpm). Concurrently, SpO₂ was 99%, BP was 90/55 mmHg, and

ETCO₂ was 37 mmHg. HR further declined to 30 beats per minute and progressed to asystole within approximately 10 seconds. Monitor recordings confirmed the transition from bradycardia to asystole (Fig. 1). Clinical examination revealed absence of radial pulse. Suspension laryngoscope was immediately removed, external chest compressions were initiated, and 0.5 mg of intravenous atropine was administered. After approximately 30 seconds, the sinus rhythm returned to 40 beats per minute and gradually increased to 60 beats per minute within the following minute. BP stabilized at 100/60 mmHg and HR remained between 65 and 70 beats per minute. Following clinical reassessment, surgery was resumed 5 minutes later. The suspension laryngoscope was reinserted using a gentler technique and avoiding excessive neck extension, while maintaining anesthetic depth at MAC of 0.9. The procedure subsequently progressed without complications, and no further episodes of bradycardia or asystole were observed.

Postoperatively, the patient remained alert and hemodynamically stable, with no chest pain, dyspnea, or neurological deficits. Electrocardiography and cardiac biomarkers were within normal limits. He was discharged in good condition on postoperative day 1. At a 2-week follow-up, he remained asymptomatic, with no evidence of recurrent events or complications (Table 1).

Discussion and conclusion

Asystole during suspension laryngoscopy is extremely rare but can occur suddenly and be life-threatening. In two prospective studies involving 100 and 339 patients undergoing suspension laryngoscopy [1, 8], no cases of

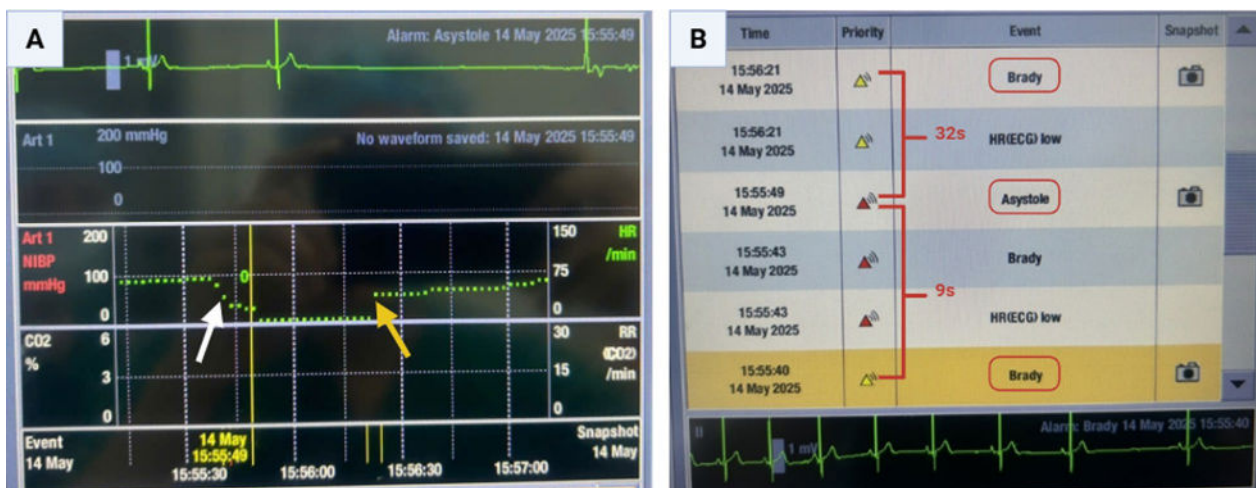


Fig. 1 Progression of bradycardia and asystole during suspension laryngoscopy. **A** Monitor screenshot illustrating the transition from bradycardia to an isoelectric line (asystole) and subsequent recovery of sinus rhythm. The white arrow indicates the onset of bradycardia; the yellow line marks the onset of asystole; and the yellow arrow shows sinus rhythm recovery following intervention. **B** Alarm event log demonstrating bradycardia onset, progression to asystole 9 seconds later, and recovery of sinus rhythm after approximately 32 seconds

Table 1 Timeline of perioperative events and asystole management

Time period	Event/intervention	Clinical findings/outcome
Preoperative	Pre-anesthetic assessment	ASA II, Mallampati II; no abnormal findings on physical examination or ECG
Pre-induction	Standard monitoring applied	Sinus rhythm 65 beats per minute; BP 150/80 mmHg; SpO ₂ 98%
Induction	Sufentanil 15 mcg, propofol 150 mg, rocuronium 50 mg were administered	Smooth induction, stable hemodynamics
Pre-suspension	Sufentanil 10 mcg administered	Sinus rhythm 58 beats per minute; BP 100/60 mmHg; 0.9 MAC
Suspension	Suspension laryngoscope applied	Severe bradycardia progressing to asystole within 9 seconds; flatline ECG, no palpable pulse
Immediate management (40 seconds after suspension)	Suspension removed, chest compressions, atropine 0.5 mg intravenous (Adrenaline prepared, but precluded by immediate recovery)	Sinus rhythm was returned 32 seconds after intervention at 40 beats per minute, increasing to 60 beats per minute within 1 minute; BP 100/60 mmHg
5 minutes after recovery	Surgery resumed with gentler suspension, avoiding neck overextension	Stable HR 65–70 beats per minute; no recurrence of bradycardia or asystole
Postoperative	Recovery and observation	Conscious and hemodynamically stable; ECG and postoperative cardiac biomarkers were normal; discharged on postoperative day 1
Follow-up (2 weeks)	Outpatient evaluation	In good health; no recurrent events or complications

ASA American Society of Anesthesiologists, ECG electrocardiogram, BP blood pressure, FIO₂ fraction of inspired oxygen, MAC minimum alveolar concentration, SpO₂ oxygen saturation, HR heart rate

asystole were reported, and this complication has only been described in isolated case reports [3, 4]. In the present case, bradycardia progressed to asystole during suspension laryngoscopy. Complete recovery of sinus rhythm following prompt removal of the instrument, chest compressions, and intravenous atropine administration suggested that a vagal reflex (VR) was the primary mechanism. Typically, suspension laryngoscopy induces a sympathetic response, resulting in tachycardia and elevated BP [2]. In rare instances, excessive stimulation of the laryngeal region, which is richly innervated by the

vagus nerve (cranial nerve X), may trigger a VR leading to bradycardia or even asystole [2, 9].

Notably, the patient’s HR decreased to below 60 beats per minute immediately before suspension laryngoscopy, following the administration of an additional 10 mcg of sufentanil. Sufentanil may enhance parasympathetic dominance by attenuating efferent sympathetic activity. Consequently, it may increase the risk of VR upon laryngeal stimulation [2, 10]. In this case, sufentanil-induced bradycardia and strong laryngeal stimulation likely acted synergistically to trigger a vagal reflex (Fig. 2).

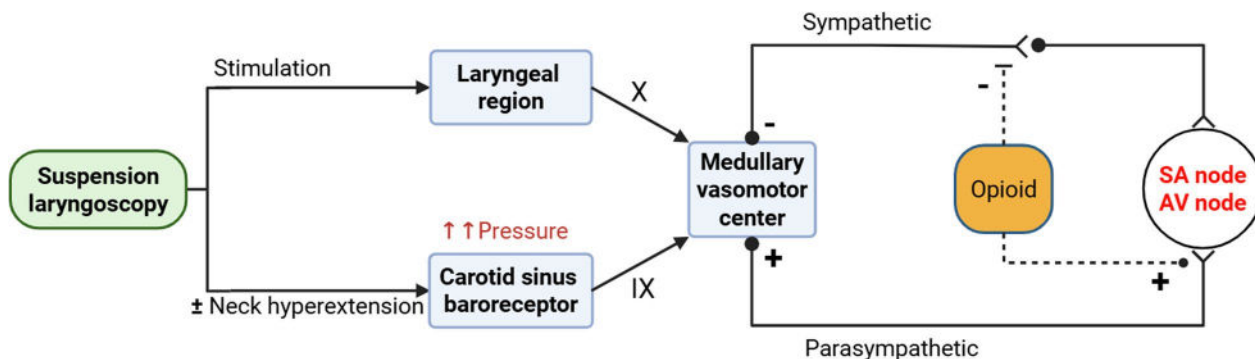


Fig. 2 Mechanisms of vagally mediated asystole during suspension laryngoscopy. Stimulation of the laryngeal region via the vagus nerve (X) and/or neck hyperextension activating the carotid sinus baroreceptor via the glossopharyngeal nerve (IX) converge at the medullary vasomotor center, resulting in increased parasympathetic and reduced sympathetic outflow. Opioids may further enhance vagal dominance, leading to sinoatrial (SA) and atrioventricular (AV) node depression and subsequent bradycardia or asystole

Furthermore, carotid sinus hypersensitivity (CSH) should be considered a contributing factor, particularly in older hypertensive male patients [11]. Hyperextension of the neck during suspension laryngoscopy may stretch and compress the carotid sinus, stimulating the glossopharyngeal nerve (cranial nerve IX), and resulting in sympathetic inhibition and increased vagal tone [3, 6]. Although these two mechanisms involve different stimuli, both converge at the medullary vasomotor center, resulting in enhanced parasympathetic and reduced sympathetic activity. Consequently, they share similar clinical manifestations and management strategies, particularly the immediate removal of the offending instrument, which simultaneously eliminates both triggers (Fig. 2). Notably, asystole has also been attributed to excessive neck extension during thyroid surgery [7], indicating that even in the absence of pharyngeal stimulation, hyperextension alone may trigger such a reflex. This suggests that CSH may act as an independent mechanism, and that even with anesthesia sufficient to suppress reflex responses, excessive neck hyperextension may still provoke such a response.

Our case illustrates that asystole was successfully avoided when the suspension laryngoscope was reinserted using a gentler technique and with minimized cervical extension. A similar observation was reported by Latuska [6], in which repeated episodes of severe bradycardia occurred despite prophylactic administration of glycopyrrolate. Only when the procedure was repeated with reduced suspension force and less neck extension did the cardiovascular events not recur. Taken together, both cases suggest that careful surgical technique with avoidance of excessive cervical stretching may represent a more reliable preventive approach against reflex-induced cardiac events during suspension laryngoscopy. Notably, in the report by Latuska *et al.*, severe bradycardia recurred despite prophylactic glycopyrrolate, raising doubts about the preventive efficacy of vagolytic agents in this context.

Considering these potential mechanisms, alternative nonvagal causes, including those listed among the “Hs and Ts,” were excluded on the basis of comprehensive perioperative evaluation [12]. Hemodynamics and oxygenation remained stable, perioperative ECGs showed no ischemic changes, postoperative cardiac biomarkers were normal, and airway pressures and preoperative tests were unremarkable (Table 2).

This case highlights the importance of continuous heart rate monitoring during suspension laryngoscopy. Asystole developed within seconds of suspension laryngoscopy, despite stable hemodynamics during induction and intubation [5]. Prompt recognition and management by the anesthesia team led to complete

Table 2 Differential diagnoses of cardiac arrest

Hs	Ts
Hypoxemia	Toxins (anaphylaxis/anesthetics)
Hypovolemia	Tension pneumothorax
Hyper-/hypokalemia	Pulmonary thrombosis/embolus
Hydrogen ion excess	Coronary thrombosis
Hypothermia	Tamponade
Hypoglycemia	Trauma
Malignant hyperthermia	QT prolongation
Hypervagal	Pulmonary hypertension

recovery without complications. This case also emphasizes the importance of a proactive intraoperative emergency plan, immediate availability of resuscitation drugs, and operating room setup that enables rapid response to cardiac arrest [4].

In conclusion, this case underscores that reflex asystole during suspension laryngoscopy may be effectively prevented through a gentle surgical technique that avoids excessive neck extension, together with vigilant monitoring and readiness for immediate intervention to ensure patient safety.

Abbreviations

HR	Heart rate
VR	Vagal reflex
CSH	Carotid sinus hypersensitivity
BP	Blood pressure

Acknowledgements

Not applicable.

Author contributions

QQL was involved in the perioperative anesthetic management of this patient. QQL and TQP collected the clinical data and drafted the manuscript as major contributors. QQL, YTTP, and KKL critically reviewed and revised the manuscript. All authors read and approved the final manuscript.

Funding

Not applicable.

Data availability

No datasets were generated or analyzed during the current study.

Declarations

Ethics approval and consent to participate

This retrospective case report was conducted in accordance with the Declaration of Helsinki. Formal review and approval by an ethics committee were not required, in accordance with institutional policy. Written informed consent was obtained from the patient for publication.

Consent for publication

Written informed consent was obtained from the patient for publication of this case report and any accompanying images. A copy of the written consent is available for review by the Editor-in-Chief of this journal.

Competing interests

The authors declare no competing interests.

Received: 5 September 2025 Accepted: 30 November 2025

Published online: 19 December 2025

References

1. Klussmann JP, Knoedgen R, Wittekindt C, Damm M, Eckel HE. Complications of suspension laryngoscopy. *Ann Otol Rhinol Laryngol*. 2002;111(11):972–6.
2. Dabbous AS, Baissari MC, Nehme PW, Esso JJ, Abu Leila AM. Perioperative reflex bradycardia and cardiac arrest. *Middle East J Anaesthesiol*. 2014;22(4):353–60.
3. Matsunobu T, Okubo K, Saito K. Vagal reflex-induced asystole during suspension laryngoscopy: a rare complication. *J Nippon Med Sch*. 2025. https://doi.org/10.1272/jnms.JNMS.2025_92-604.
4. Justi Cassettari A, Campos E Santos EC, Semenzati GO, Crespo AN. Asystole during suspension laryngoscopy: case report, literature review, and prophylactic strategies. *Case Rep Otolaryngol*. 2020;2020:1–4.
5. Ko HB, Lee DY, Lee YC. Severe bradycardia during suspension laryngoscopy performed after tracheal intubation using a direct laryngoscope with a curved blade -A case report. *Korean J Anesthesiol*. 2010;59(2):116.
6. Latuska RF, Kuhl NO, Garrett CG, Berry JM, Gelbard A. Severe bradycardia associated with suspension laryngoscopy. *Laryngoscope*. 2016;126(4):949–50.
7. Lilitis E, Papaioannou A, Hatzimichali A, Spyridakis K, Xenaki S, Chalkiadakis G, Chrysos E. A case of asystole from carotid sinus hypersensitivity during patient positioning for thyroidectomy. *BMC Anesthesiol*. 2015. <https://doi.org/10.1186/s12871-016-0255-5>.
8. Wenig BL, Raphael N, Stern JR, Shikowitz MJ, Abramson AL. Cardiac complications of suspension laryngoscopy. Fact or fiction? *Arch Otolaryngol Head Neck Surg*. 1986;112(8):860–2.
9. Yoshida Y, Tanaka Y, Hirano M, Nakashima T. Sensory innervation of the pharynx and larynx. *Am J Med*. 2000;108(Suppl 4a):51s–61s.
10. Cardinal V, Martin R, Tétrault JP, Colas MJ, Gagnon L, Claprood Y. Severe bradycardia and asystole with low dose sufentanil during induction with sevoflurane: a report of three cases. *Can J Anaesth J Can D'anesthésie*. 2004;51(8):806–9.
11. Kharsa A, Wadhwa R: Carotid Sinus Hypersensitivity. In: *StatPearls*. edn. Treasure Island (FL) ineligible companies. Disclosure: Roopma Wadhwa declares no relevant financial relationships with ineligible companies.: StatPearls Publishing Copyright © 2025, StatPearls Publishing LLC.; 2025.
12. Moitra VK, Einav S, Thies K-C, Nunnally ME, Gabrielli A, Maccioli GA, Weinberg G, Banerjee A, Ruetzler K, Dobson G, et al. Cardiac arrest in the operating room: resuscitation and management for the anesthesiologist: part 1. *Anesth Analg*. 2018;126(3):876–88.

Publisher's Note

Springer Nature remains neutral with regard to jurisdictional claims in published maps and institutional affiliations.